13th Batch

Exam Committee

NEU 241 Final MCQs

DISCLAIMER: The MCQ portion of the exam was difficult, so we were unable to remember a lot of the questions. The questions that we were unable to collect mostly consisted of Anatomy (strokes specifically) and neurology. We tried our best to collect the most we could. Good luck in your exam <3. For any concerns, feel free to contact me on email: khamsho@alfaisal.edu

NEU final MCQs 62/109

1. A 49-year-old woman presents to the ER after getting shot in the back during a robbery. On imaging, it was revealed that she suffered from a hemi section of the spinal cord. Which of the following findings would be noted below the level of the lesion?
    a. Ipsilateral loss of pain
    b. Ipsilateral loss of temperature
    c. Contralateral loss of crude touch
    d. Ipsilateral loss of vibration
    e. Ipsilateral pressure

    Answer: D

2. Which of the following pictures represents the Kernig sign:

A

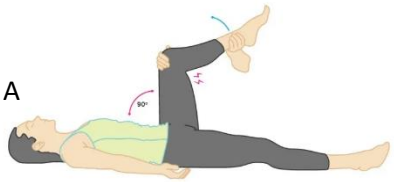

B

C

D

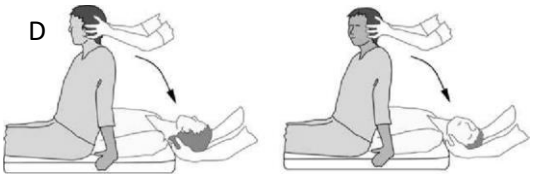

Answer: A

3. A 15-year-old boy presents with ataxia and has a history of diabetes mellitus. Which of the following is the correct diagnosis:
    a. Huntington's disease
    b. Leigh syndrome
    c. Friedrich Ataxia
    d. Gaucher disease

Answer: C

4. A 15-year-old suffers from painful muscle cramps, weakness, and fatigue after playing soccer. After resting for a while, he was able to continue playing. After visiting his doctor, it was noted that he had

elevated serum creatine kinase (CK). Which of the following is the diagnosis:

a. McArdle disease
b. Pompe disease
c. Duchenne muscular dystrophy
d. Myasthenia gravis
e. Myotonic dystrophy

Answer: A

5. Ahmad is a psychiatrist who feels annoyed with his aggressive patient. Later on, when he thought about it he realized the patient reminded him of his ex-wife. What defense mechanism is the psychiatrist demonstrating?
    a. Transference
    b. Countertransference
    c. Identification with aggressor
    d. Projection
    e. Reaction Formation

    Answer: B

6. Mechanism of action of methylphenidate:
    a. Blocks norepinephrine, serotonin, dopamine transporters equally
    b. Blocks norepinephrine and serotonin transporters only

c. Blocks norepinephrine and dopamine transporters mainly
d. Blocks norepinephrine and serotonin transporters mainly

Answer: C

7. Which of the following drugs binds to GABA complex increasing the chloride channeling opening average time:
    a. Phenobarbital
    b. Diazepam
    c. Alcohol
    d. Ramelteon

Answer: A

8. Which of the following has anesthetic and analgesic effects?
    a. Propofol
    b. Fentanyl
    c. Etomidate
    d. Ketamine

Answer: D

9. A depressed white 60-year-old widower presents to the psychiatric ward. Which of the following steps should be taken right away?
    a. Give medication immediately
    b. Assess risk of suicide
    c. Do required medical work up first
    d. Reassure him and send him home

Answer: B

10. Trazadone is classified as which of the following drugs:
    a. SSRI
    b. SNRI
    c. TCA
    d. Atypical antidepressant
    e. MOA-inhibitor

Answer: D

11. Which of the following drugs would you use for treatment-resistant depression:
    a. Amitriptyline
    b. Escitalopram
    c. Fluoxetine
    d. Phenelzine

Answer: A

12. A 69-year-old woman presents to the psychiatrist with trouble sleeping, eating, and felt nervous four days before a major exam. She is worried about her symptoms. What's the next step to do?
    a. Start her on SSRI's
    b. Reassure her it's normal and send her home
    c. Do a blood workup to check for thyroid dysfunction
    d. Tell her to stop worrying about the exam

Answer: B (We're not sure of the answer, but about 99% of the people I spoke to picked B; contact @kbeefsho or @ibrodhaibi on twitter for discussion)

13. Virchow Robin space is between perforating arteries and which structure?
    a. Arachnoid mater
    b. Pia mater
    c. Dura mater
    d. Subarachnoid space

Answer: B

14. Baby presents with seizures after the mother has presented with lesions in the genital region. Assuming that the baby was infected by a virus, what is the property of this virus?
    a. Latency in neuronal tissue
    b. Replicate in the intestines
    c. Infect through respiratory droplets
    d. Transmitted feco-orally

Answer: A

15. A patient presents to the doctor to get tested for cervical cancer multiple times after their coworker at work got diagnosed years ago. Every time the patient feels a little bit of discomfort in the abdomen, they worry that it might cancer.
    a. Somatic symptom disorder
    b. Malingering
    c. Illness anxiety disorder
    d. Factitious disorder

Answer: C

16. A patient presents with symptoms of depression and is anxious and wants to leave the hospital. What you do next?
    a. Ask why he is anxious
    b. Send him home
    c. Give him sertraline
    d. Be compassionate with him

Answer: D (we're not sure of the answer, but it did probably get appealed because this lecture was not included in the blueprint)

17. Which of the following is the correct pathway for sensitization in Aplysia?
    a. Binding of serotonin to Gs-protein-coupled receptor → increased in cAMP → activation of PKA → phosphorylation of K+ channels
    b. Binding of glutamate to receptors NMDA receptors → increased Ca++ influx → insertion of AMPA receptors
    c. Binding of serotonin to Gs-protein-coupled receptor → increased in cAMP → activation of PKA → phosphorylation of transcriptional activator CREB-1
    d. Activation of AMPA receptors by glutamate → increased influx of Na+ → downregulation of AMPA receptors

Answer: A

18. A drug that blocks t-type calcium channels leading to decreased glutamate release. Which of the following is this drug?
    a. Gabapentin
    b. Valproate
    c. Lamotrigine
    d. Ethosuximide

Answer: D

19. Serotonin decreases pain by which of the following pathway?
    a. Descending analgesic pathway
    b. Gate control theory
    c. Spinothalamic pathway
    d. Neurons from the dorsal root ganglion

Answer: A

20. A 69-year-old man presents to the ER respiratory depression. He was prescribed diazepam to treat his crippling anxiety. Which of the following drugs should be administered?

a. Lorazepam
b. Phenytoin
c. Naloxone
d. Flumazenil

Answer: D

21. One contraindication of morphine is?

a. Vitamin C deficiency
b. Intestinal obstruction
c. Broken bone
d. Diarrhea

Answer: B

22. Which of the following is a CSF production site?

a. Roof of third ventricle
b. Choroid plexuses
c. Cerebral aqueduct
d. Subarachnoid space
e. Central canal

Answer: B

23. A woman came with a severe headache into the emergency department. The ER resident suspected a subarachnoid hemorrhage. A plain CT of the head returned normal. What is the next best step?
    a. CT angiogram
    b. MRI Flair
    c. Lumbar puncture
    d. Contrast CT
    e. Doppler angiography

Answer: We don't know, like genuinely lmao (most picked B or C but it's all unfounded)

24. Which of the following types of seizures would be an indication for a boy who presented with a first-time seizure to do a CT scan?
    a. Generalized tonic-clonic seizure
    b. Partial seizure
    c. Absence seizure
    d. Myoclonic seizure

Answer: No clue no one knows (We had a guy's mom who is a neurologist answer this question and she said partial seizure)

25. The primary underlying problem of Parkinson's disease is:
    a. Unbalanced alpha and beta sheet structures
    b. Alpha synuclein aggregation
    c. Increased tonic discharge from GPi
    d. Multiple infarcts affecting the hippocampus

Answer: B

26. Formation of explicit short-term memory to long-term memory is initiated in?
    a. Prefrontal cortex
    b. Hippocampus
    c. Amygdala
    d. Orbitofrontal cortex
    e. Thalamus

Answer: B

27. A patient presents with meningitis. A lumbar puncture was performed, and CSF shows the following picture. Which of the following investigation should be done to further identify the causative agent:
    a. Gram stain
    b. Sliver stain
    c. PAS stain
    d. India ink
    e. Acid fast stain

Answer: E

28. Which of the following findings in the CSF would warrant further investigation: Protein: 30 mg/100 mL | Glucose: 60 mg/100 mL | Cell count: 3 | Pressure: 260 H2O?
    a. Protein
    b. Glucose

c. CSF is normal
d. Pressure
e. Cell count

Answer: D

29. A woman just gave birth and started feeling slight depressive symptoms within a month of her delivery, with no effect on social activity. Which of the following is the correct diagnosis?
    a. Post-partum depression
    b. Post-partum blues
    c. Major depressive disorder
    d. Dysthymia
    e. Post-partum psychosis

Answer: B

30. Patient with trouble remembering stuff that's been said to him is diagnosed with Alzheimer's disease. Which of the following drugs, if prescribed, could possibly lead to sleep disturbances?
    a. Donepezil
    b. Memantine
    c. Rivastigmine
    d. Ropinirole

e. Ramelteon

Answer: A

31. A woman presents with inability to stay asleep with low mood, loss of interest in normal activities, increased appetite, constant fatigue. Her symptoms worsened after the birth of her 2 year-old child. Which of the following is the correct diagnosis?
    a. Major depressive disorder
    b. Postpartum depression
    c. Post-partum blues
    d. Bipolar II
    e. Cylcothymia

Answer: A

32. Which drug inhibits the excitotoxic effects of Alzheimer's disease?
    a. Amantadine
    b. Donepezil
    c. Memantine
    d. Rivastigmine

Answer: A

33. A doctor performed an EEG on a 4 year-old child. 3 Hz spike dome readings were found on the EEG. Which of the following is the correct diagnosis?
    a. Temporal lobe epilepsy
    b. Absence Seizure
    c. Jacksonian seizure
    d. Juvenile myoclonic epilepsy
    e. Generalized tonic-clonic seizure

Answer: E

34. A 16-year old girl with anxiety presented to a psychiatrist. Her childhood was brutal with an abusive father. Hearing the girl's story, the psychiatrist started feeling protective towards the patient in a father-like figure. What defense mechanism is demonstrated?
    a. Countertransference
    b. Transference
    c. Reaction formation
    d. Projection
    e. Splitting

Answer: A

35. The Rhombic lips give rise to which of the following structures:

a. Cerebral hemispheres
b. Pons
c. Cerebellum
d. Medulla
e. Spinal cord

Answer: C

36. A patient kept complaining of symptoms of diarrhea and abdominal pain. Multiple lab investigation turned out negative. The patient had switched doctors at least 69 times. Which of the following is the correct diagnosis?

a. Malingering
b. Somatoform symptom disorder
c. Illness anxiety disorder
d. Factitious disorder

Answer: B

37. A 16-year-old girl presents to the ER with depression. She was thin and had hair-like projection from her neck. She mentioned that she exercises very heavily and eats only 300 calories a day. Which of the following is the correct diagnosis?

a. Bulimia nervosa
b. Binge eating disorder
c. Somatic symptom disorder
d. Major depressive disorder
e. Anorexia nervosa

Answer: E

38. A 17-year-old girl presents to the ER with unstable vitals. Her labs show metabolic alkalosis and her hands showed dorsal calluses. She mentioned that she has been on a strict diet and exercises excessively. Her BMI is 20. What is the diagnosis?

a. Anorexia nervosa
b. Bulimia nervosa
c. Binge eating disorder
d. Bipolar I
e. Schizophrenia

Answer: A

39. A patient suffering from anorexia nervosa started treatment. The resident accidentally infused too many nutrients too quickly. Which of the following is the most dangerous complication as a result of this?

a. Weight gain
b. Seizures
c. Electrolyte imbalance
d. Strokes

Answer: C

40. Which of the following would be most concerning in a patient suffering from anorexia nervosa?

a. Hypotension and bradycardia
b. Exercise regiment
c. Weight fluctuation
d. Amenorrhea

Answer: A

41. Parasympathetic fibers carried by the oculomotor nerve originate from where?

a. Superior salivatory nucleus
b. Inferior salivatory nucleus

c. Dorsal motor nucleus
d. Edinger-Westphal nucleus
e. Nucleus of tractus solitarius

Answer: D

42. A 56-year-old patient presents to the ER with complete loss of sensation on the right side of the body. A few days later, the patient presented with freezing pain on the same side. Which of the following structures could be damaged?
    a. Left Thalamus
    b. Right thalamus
    c. Left internal capsule
    d. Left midbrain
    e. Right pons

Answer: A

43. A 56-year-old patient presents to the ER with complete loss of motor function on the right side of the body. He suffered from a stroke. Which of the following sites could be damaged?
    a. Right internal capsule
    b. Left thalamus
    c. Right thalamus

d. Left internal capsule
e. Left medial primary motor cortex

Answer: D

44. A patient presented to the ER after her therapist left the country. She attempted to call him at least 40 times, leaving a voice note stating that she will kill herself if he does not come back. Investigations were unremarkable for any substances or medical diseases. Which of the following is the correct diagnosis?
    a. Histrionic personality disorder
    b. Narcissistic personality disorder
    c. Borderline personality disorder
    d. Bipolar I
    e. Bipolar II

Answer: C

45. Which of the following is a negative symptom of schizophrenia?
    a. Thought-blocking
    b. Though-broadcasting
    c. Hallucinations
    d. Delusions
    e. Disorganized thinking

Answer: A

46. A patient presented with a complaint of dizziness when turning in bed and waking up in the morning. The dix-hallpike maneuver showed nystagmus in less than a minute. Which of the following is the correct diagnosis?
    a. Meniere's disease
    b. Vestibular neuritis
    c. Schwannoma
    d. BPPV

Answer: D

47. A patient had a mutation in the VHL gene. Which of the following is the most likely finding in this patient?
    a. Hemangioblastoma
    b. Rhabdomyoma
    c. Schwannoma
    d. Medulloblastoma

Answer: A

48. A 10-year-old patient presents with ataxia. Imaging shows a mass behind the cerebellum. Which of the following is the most likely diagnosis?
    a. Medulloblastoma
    b. Glioblastoma multiforme
    c. Oligodendroglioma
    d. Ependymoma
    e. Pilocytic astrocytoma

Answer: A

49. A 59-year-old alcoholic presents to the ER with ataxia, confusion, dysdiadochokinesia, and a tremor when performing the finger-to-nose-to-finger test. Which of the following nuclei could be affected?
    a. Dentate nucleus
    b. Nuclei fastigii
    c. Emboliform nucleus
    d. Globose nucleus
    e. Nucleus ambiguous

Answer: B

50. A 50-year-old man fell down the stairs on his head. Weeks later, he complained of a headache and tingling sensation in his limbs. A CT scan is shown below. Which of the following is the diagnosis?

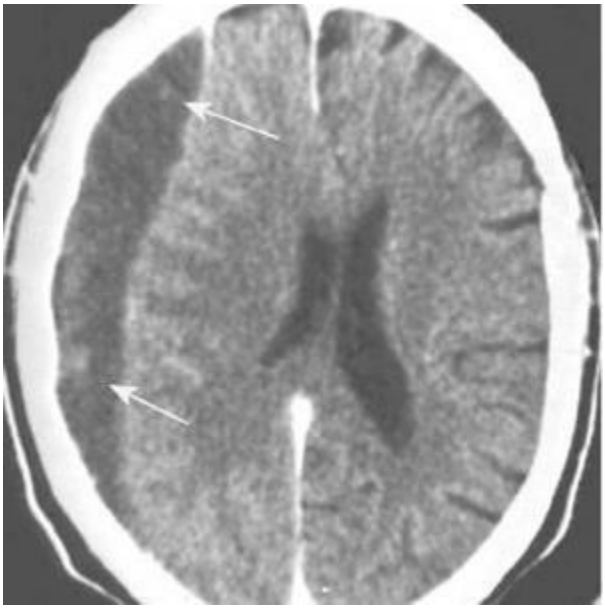

a. Epidural hemorrhage
b. Subdural hemorrhage
c. Subarachnoid hemorrhage
d. Intraparenchymal hemorrhage
e. Extracranial hemorrhage

Answer: B

51. A patient suffered from a car crash. He presented to the clinic with the worst headache of his life. Hours later, he died. A CT scan before his unfortunate demise is shown below. What‘s the diagnosis?

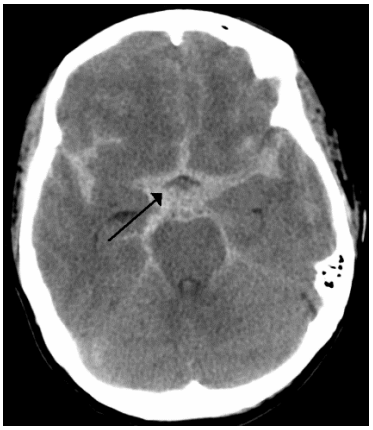

a. Epidural hemorrhage
b. Subdural hemorrhage
c. Subarachnoid hemorrhage
d. Intraparenchymal hemorrhage
e. Extracranial hemorrhage

Answer: C

52. A 30-year-old patient presented with a headache in the morning. She was diagnosed with a tumor. Months later, the patient expired. Histology studies on autopsy are shown below. What is the diagnosis?

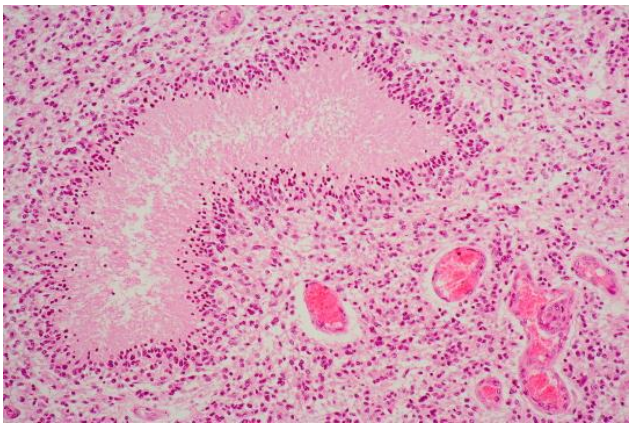

a. Ependymoma

b. Pilocytic astrocytoma
c. Glioblastoma multiforme
d. Schwannoma
e. Medullablastoma

Answer: C

53. Activation of the beta-2 receptors results in which of the following secondary messengers?
a. IP3
b. Ca++
c. DAG
d. cAMP
e. cGMP

Answer: D

54. A 30-year-old office worker started experiencing headaches recently. These episodes were severe and impaired on her ability to finish her tasks at work. After meeting her primary care physician and undergoing an examination, she revealed that the headache was on the right side only. It was also revealed that the patient feels relieved when she sits in a dark room. What's the diagnosis?

a. Tension headache
b. Cluster headache
c. Migraine headache
d. Secondary headache

Answer: C

55. Schizophrenia is considered a disease targeting:
a. Cognition
b. Memory
c. Thinking
d. Concentration
e. Orientation

Answer: C

56. A 60-year-old patient presents to the doctor with a complaint about being unable to feel their left face. When asked to point with their left hand at an object, they couldn't move it, however, using the right hand was possible to perform this action. Based on this presentation, the lesion is likely to be involved in which part of the brain?
a. Frontal lobe
b. Right parietal lobe

c. Right frontal and parietal lobe
d. Left frontal and temporal lobe
e. Temporal lobe

Answer: C

57. A 60-year-old patient presents to the doctor with a complaint about being unable to feel their left face. When asked to point with their left hand at an object, they couldn't move it, however, using the right hand was possible to perform this action. Based on this presentation, a stroke would be most likely affecting which artery?
    a. Left anterior cerebral artery
    b. Right posterior cerebral artery
    c. Right anterior cerebral artery
    d. Right middle cerebral artery
    e. Left middle cerebral artery

Answer: D

58. Regular use of which of the following substances may contribute to the development of motivational syndrome, feeling stoned and more passive inward personality characteristics?
    a. Benzodiazepine
    b. Alcohol

c. Amphetamine
d. Cocaine
e. Marijuana

Answer: E

59. Which one of the following cellular events will occur in long term depression?
a. More AMPA receptors will be inserted
b. Calcineurin will be activated
c. CAMKII will be activated
d. N2RA subunits of NMDA receptors in the hippocampus will be bound
e. High postsynaptic Ca++ influx

Answer: B

60. A 53-year-old man with long standing schizophrenia has failed therapy with both first and second-generation antipsychotic agents. He still has significant problems with his mood, delusions and hallucinations. He had agranulocytosis. Which of the following drugs is he on?
a. Donepezil
b. Olanzapine

c. Clozapine
d. Risperidone
e. Quetiapine

Answer: C

61. A patient with communicating hydrocephalus. CT scan reveals marked enlargement of the lateral and third ventricles and a small fourth ventricle. Which of the following will be obstructed in this case?
    a. Foramen of Monroe
    b. Aqueduct of Sylvius
    c. Foramen Luschka
    d. Third ventricle

Answer: B

62. A patient was hospitalized due to a severe car crash. Three days into his stay at the hospital, the patient became agitated, angry, and aggressive. Which of the following could be going on in this patient?
    a. Opioid withdrawal
    b. Delirium tremens
    c. Episode of psychosis
    d. Cocaine withdrawal

Answer: B

According to all known laws of medicine, there is no way a brain should be able to think. Its neurons are too small to push its fat little neurotransmitters across the synapse. The brain, of course, thinks anyways because brains don't care what humans think is impossible

Acknowledgements:

- **Special thank you for exam committee members for doing your best in collecting these questions**
- **Special thanks to Ibrahim Alodhaibi for helping me collect, brainstorm, and phrase the questions here**

- **Special thanks to Tariq Makhzoum for writing the masterpiece in red above**

Feel free to contact me through email if you have any questions: khamsho@alfaisal.edu. We wish you all the best. We hope your exam goes better than ours <3